

EP CASE REPORT

Life-threatening junctional ectopic tachycardia storm after injury around the atrioventricular node successfully treated by mini-pulse corticosteroid therapy

Masateru Takigawa¹*, Masahiko Goya¹, Junji Yamaguchi¹, Yasuhiro Shirai¹, Claire A. Martin², and Tetsuo Sasano¹

¹Department of Cardiovascular Medicine, Tokyo Medical and Dental University, 1-5-45 Yushima, Bunkyo-ku, Tokyo 113-8510, Japan; and ²Department of Cardiology, Royal Papworth Hospital NHS Foundation Trust, Cambridge, UK

* Corresponding author. Tel: +81338136111. E-mail address: teru.takigawa@gmail.com

We present a 32-year-old woman, who developed a life-threatening junctional tachycardia storm after ablation for fast-slow atrioventricular nodal reentrant tachycardia (AVNRT).

This patient was admitted for electrophysiological (EP) study and ablation for paroxysmal palpitation. Although the EP study demonstrated both antegrade and retrograde pathways with a jump, tachycardia was not induced, likely due to transient mechanical AV-block (Figure 1A). While the antegrade slow-pathway (SP) was being anatomically ablated, fast-slow AVNRT was spontaneously induced (Figure 1B). Although anatomical antegrade-SP modification was initially performed during sinus rhythm by a non-irrigated catheter (15–30 W, 5 min in total; Figure 1B, pink and brown dots), the tachycardia remained. The catheter was changed to an irrigated catheter, and radiofrequency application at the earliest retrograde-SP activation at the inferoposterior coronary sinus terminated the tachycardia within 1 min (Figure 1B, green dot), and 3 min of ablation was added. Although AV conduction had not completely recovered (Figure 1C [1]), AVNRT was not inducible at the end of the procedure.

Three hours after the procedure, narrow QRS tachycardia [heart rate (HR) = 100 b.p.m.]

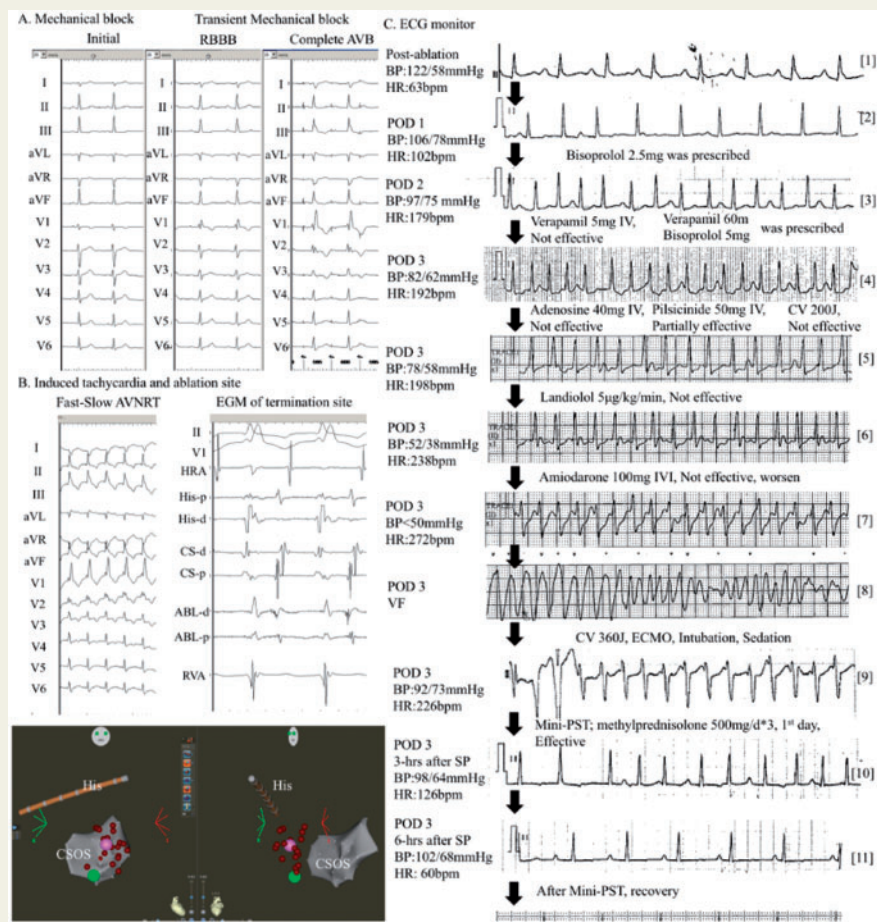


Figure 1 (A) The ECG during catheter placement. AV conduction was normal at initiation, turning to the complete AV-block via RBBB. AV conduction recovered to RBBB 10 min later, but did not normalize. (B) Fast-slow nodal reentrant tachycardia with RBBB. Although antegrade slow-pathway modification (pink dot and brown dots) did not prevent the tachycardia, ablation at the site of earliest atrial activation at the inferoposterior CS (green dot) terminated the tachycardia within 1 min. (C) The time course of ECG monitoring and treatment after ablation. BP, blood pressure; CS, coronary sinus; CV, cardioversion; ECG, electrocardiogram; ECMO, extracorporeal membrane oxygenation; HR, heart rate; HRA, high right atrium; IV, intravenously; IVI, intravenous infusion; POD, post-operative day; PST, pulsed-steroid therapy; RBBB, right bundle branch block; RVA, right ventricular apex; VF, ventricular fibrillation.

with occasional P-QRS dissociation was observed (Figure 1C [2]). Although recurrent AVNRT and dual AV nodal non-reentrant tachycardia were still possible, junctional ectopic tachycardia (JET) was strongly suspected, and the patient was discharged with rate control medication of 2.5 mg bisoprolol. On post-operative day (POD)-2, she visited the outpatient clinic with an increased HR of 179 b.p.m. Figure 1C [3], and 60 mg verapamil and 5 mg bisoprolol daily were started. On POD-3, the patient returned to the emergency department in a pre-shock state (Figure 1C [4]). Neither pilisicinide nor adenosine intravenously (IV) nor cardioversion terminated the tachycardia (Figure 1C [5]). Despite landiolol (5 µg/kg/min) IV-infusion (IVI), the HR increased to 238 b.p.m. and the patient deteriorated into shock status (Figure 1C [6]). Amiodarone (100 mg/20 min) IVI was ineffective, and the electrocardiogram (ECG) deteriorated to ventricular fibrillation without any identifiable causes from the blood tests (Figure 1C [7, 8]). The patient was defibrillated, and extracorporeal membrane oxygenation (ECMO) was introduced. Since the frequent firing of the JET was still observed despite sedation (Figure 1C [9]), pulsed-steroid therapy with methylprednisolone sodium succinate was started. Three hours after the first 500 mg had been administered, her HR started to decrease (Figure 1C [10]) and 6 h later, the HR reached 60 b.p.m. (Figure 1C [11]) even though AV dissociation was still observed. On POD-6, after three consecutive days of 500 mg-steroid steroid infusion, complete synchronized AV conduction recovered with the disappearance of JET (Figure 1C [12]). Since the patient refused a repeat EP study before discharge, an exercise-stress test was performed instead, showing no inducible arrhythmia. Frequent tele-monitoring found no arrhythmias over a 6 month follow-up period.

Junctional ectopic tachycardia is reported to be a rare but critical arrhythmia in infants and children, observed congenitally or post-operatively.¹ Post-operative JET may be seen within 72 h after surgical repair of congenital heart defects in <15% of patients.^{2,3} Direct trauma, ischaemic, or stretch injury in the region of AV node or His-bundle are believed to cause this tachycardia, and electrolyte abnormality and sympathetic tone may exacerbate the condition.^{1–3} Amiodarone is an effective and widely used antiarrhythmic for the treatment of JET.^{1–3} Other antiarrhythmics such as flecainide, procainamide, propafenone, sotalol, landiolol, nifekalant may be useful. Reducing the sympathetic tone by sedation is also important.¹

Mechanical trauma to fast and slow pathways during the ablation of AVNRT is reported to occur in 13.4% of AVNRT ablations, especially in patients aged <35 years.⁴ Although slow pathway ablation for 'benign' and 'uncomplicated' fast-slow AVNRT is an established procedure, life-threatening 'malignant' conditions can still happen. In the present case, the JET may have been caused by transient inflammation or oedema due to mechanical damage or ablation around the AV node or His-bundle, requiring resuscitation with ECMO even after treatment with several antiarrhythmics including amiodarone. Pulsed-steroid therapy may relieve the inflammation and oedema around this region, and successfully improve the condition. To the best of our knowledge, the present case is the first report to demonstrate the impact of this therapy, which should be considered as an option in refractory JET. Additionally, this case emphasizes that post-ablation JET can be life-threatening, taking an early unpredictable course after discharge. Therefore, potential guidance to manage the situation such as tele-monitoring, additional EP study, Basic life support training for family members, or wearable Implantable cardioverter-defibrillator, may be considered.

Funding

This work was supported by JSPS KAKENHI Grant Number JP20K17074.

Conflict of interest: none declared.

References

1. Kylat RI, Samson RA. Junctional ectopic tachycardia in infants and children. *J Arrhythmia* 2020;**36**:59–66.
2. Kean AC, Hazle M, LaPage MJ, Bromberg BI. Junctional tachycardia: congenital, acquired, postoperative. In: D Macdonald II, ed. *Clinical Cardiac Electrophysiology in the Young*. 2nd ed. New York: Springer; 2016. p157–69.
3. Josephson ME. Ectopic rhythms and premature depolarizations. In: ME Josephson, ed. *Josephson's Clinical Cardiac Electrophysiology: Techniques and Interpretations*. 5th ed. Philadelphia: Wolters Kluwer Health; 2016. p163–4.
4. Topilski I, Rogowski O, Glick A, Viskin S, Eldar M, Belhassen B. Catheter-induced mechanical trauma to fast and slow pathways during radiofrequency ablation of atrio-ventricular nodal reentry tachycardia: incidence, predictors, and clinical implications. *Pacing Clin Electrophysiol* 2007;**30**:1233–41.